

DOI: 10.21767/2471-8165.1000030

A Traditionally Pediatric Brain Tumor Diagnosed in the Second Trimester of Pregnancy: Index Case and Review of the Database

Federico G Mariona* and Karen L Plymel

Michigan Perinatal Associates, Maternal Fetal Medicine, Beaumont Health, Dearborn, Michigan, USA

*Corresponding author: Federico G Mariona, Michigan Perinatal Associates, Maternal Fetal Medicine, Beaumont Health, Dearborn, Michigan, USA, Tel: 1-313-593-5957; E-mail: fmariona@att.net

Received date: 24 June, 2016; Accepted date: 26 August, 2016; Published date: 29 August, 2016

Citation: Mariona FG, Plymel LK. A Traditionally Pediatric Brain Tumor Diagnosed in the Second Trimester of Pregnancy; Index Case and Review of the Database, Gynecol Obstet Case Rep. 2016, 2:2.

Abstract

Pregnancy and maternal brain tumors are an infrequent finding and a rare clinical combination. We present a case of a pilocytic astrocytoma (PA) diagnosed during the second trimester of pregnancy. This tumor is rare and is usually diagnosed in children. The occurrence in an adult presents different challenges regarding the long term behaviour of the tumor. Brain tumors during pregnancy are usually treated by a multidisciplinary team striving to protect the health of the mother while attempting to arrive at a time in pregnancy when the fetus can be safely delivered. There is a dearth of evidence-based information regarding the management of maternal intracranial tumors during gestation and no standard or established treatment. The authors recommend the reporting of the diagnosis, treatment and follow up of these cases to a National Registry to assist future patients and the health care team. Seventy-five percent of intracranial tumors in women of reproductive age present during pregnancy.

Keywords: Brain tumor; Pilocytic astrocytoma; Benign childhood tumor; Neurosurgery; Pregnancy

Introduction

In a large 36-year institutional study involving 34 pregnant women with intracranial lesions at an average maternal age of 27 ± 6 years no pilocytic astrocytomas were included [1,2]. PAs are infrequently diagnosed in pregnancy [3]. As a predominantly juvenile tumor it may have potentially serious risks for maternal outcomes and presents additional long term challenges to obstetricians. These patients are optimally diagnosed and treated by a multidisciplinary team involving obstetricians, neonatologists, radiologists, ethicists, neurologists, neurosurgeons, oncologists, maternal fetal medicine physicians and anesthesiologists. The natural history of these tumors during pregnancy is variable, from rapid maternal deterioration and neurologically unstable patients to an indolent course allowing for a conservative approach. Brain tumors in pregnancy have been reported to occur in

15/100,000 live births with variable perinatal outcomes [1]. The combination of brain tumor and pregnancy has been variably considered "in no way rare" to "extremely seldom" [4]. A query of our institution's administrative database (discharged patients) showed no brain tumors in pregnancy (ICD-9 CM 239.6, 239.7 ICD-10 D43.2 D49.7) coded for the period of January 1, 2004 to December 31, 2014, approximately 33,000 live births.

Case Report

A 31-year-old gravida 2 para 1, presented to her obstetricians for a routine prenatal care visit at 20 weeks' gestation with complaints of persistent gastric intolerance. She was diagnosed with hyperemesis gravidarum, hospitalized and treated intermittently for 8 weeks. Preeclampsia was ruled out. At 27 weeks' gestation she noticed blurred vision, diplopia, dizziness and right hand weakness. Her care was transferred to Maternal Fetal Medicine. No cranial nerves deficits or gait changes were elicited. Cranial imaging studies via CT scan without gadolinium enhancement demonstrated a 5 cm cystic-solid mass in the right cerebellar lobe with mild hydrocephaly and partially obliterated 4th ventricle (Figure 1) [5].

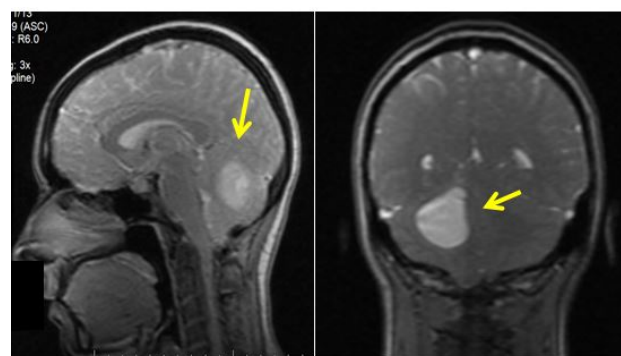


Figure 1 Maternal cranial MRI at week 26

There was no evidence of intra or peri-tumoral hemorrhage. Obstetrical ultrasound showed a single live fetus appropriately grown, at 27 weeks' gestation. Neuroradiology, neurology and neurosurgery consultation was obtained, followed by

neonatology and oncology. An additional neurosurgery consultation followed, with the tentative diagnosis of hemangioblastoma. Neurosurgery selected to access the tumor and place an Ommaya reservoir under general anaesthesia with simultaneous fetal monitoring, followed by periodic fluid aspirations for cellular diagnosis [6]. The cellular smear revealed a pilocytic astrocytoma (PA) World Health Organization (WHO) grade I. The smear report was considered not 100% diagnostic and opened to changes when tumor tissue became available. The tumor size was mildly reduced post fluid aspiration and the patient became asymptomatic. In view of the cellular diagnosis, patient's stable clinical situation and following multidisciplinary team counselling the parents opted for conservative therapy. The neurosurgical team monitored the tumor behaviour and with the agreement of the obstetrical team allow the pregnancy to continue in the absence of maternal or fetal deterioration. Three fluid evacuations through the Ommaya reservoir were performed; no malignant cells were reported. The parents were counselled regarding these findings and informed that the cellular diagnosis may be discordant with the tissue diagnosis at the time of the tumor resection. At 37 weeks' gestation she delivered a male fetus weighing 3033 g with Apgar scores of 5 and 8 at 1 and 5 minutes respectively via cesarean under general anaesthesia. A week later an arteriogram was obtained demonstrating no feeding vessels into the tumor mass. A sub occipital craniotomy was performed with piece meal excision of a right cerebellar multicystic-solid mass under intraoperative stealth navigation microscopy. A drainage system was placed in the posterior horn of the right ventricle. Frozen section and definitive tissue diagnosis reconfirmed the pilocytic astrocytoma WHO Grade I (WHO 1979), presenting the characteristic Rosenthal fibers (**Figure 2**). Periodic MRIs and CT scans without contrast were performed for follow up during the ensuing 6 months. The ventricular drain was removed. Images five months' post-surgical excision showed a cystic mass measuring 2.4 × 2.0 cm. with no evidence of new or recurrent tumor (**Figure 3**). The patient returned to her activities. She is now 20 months' post treatment and asymptomatic. The patient consent was waived as no personal identifiers are utilized.

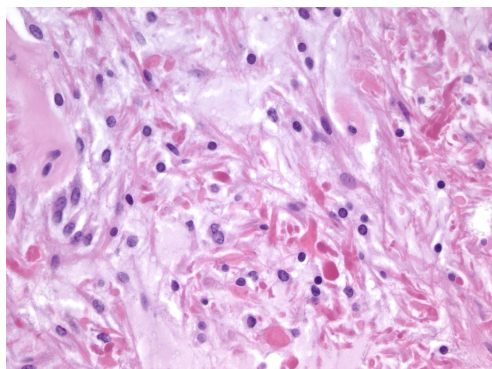


Figure 2 Rosenthal fibers (arrows)

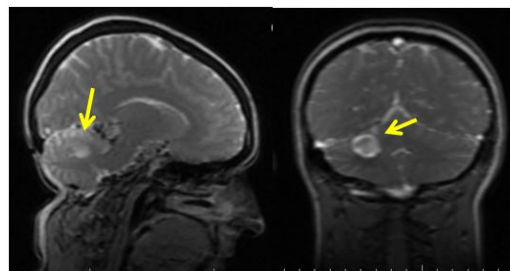


Figure 3 Maternal cranial MRI 6 months' post tumor resection

Discussion

Pilocytic astrocytoma (PA), also called juvenile pilocytic astrocytoma (JPA), or cystic cerebellar astrocytoma was arguably first described by Percival Bailey in 1924 and Harvey Cushing in 1931. None of these reports included a pregnant patient [7]. PA is rare and mostly found in children. It is defined as a juvenile, generally benign tumor that occurs most often in children and young adults. It is reported to occur in 2/100,000 children 5 to 14 years old [8]. Bar et al. reported genomic alterations in 25 cases of PA with tandem duplication on chromosome 7q34 and increased BRAF genes with levels of phosphorylated extracellular signal related kinase (ERK) and nitrogen activated protein kinase (MEK) [9]. MEK-ERK signaling may be associated with neurofibromatosis type I (NF1). JPA is seen in up to 15% of patients with this inherited syndrome, most commonly if the tumors involve the optic nerves. In children, these tumors are usually slow growing as a single or multiple cyst. When diagnosed in the adult the short and long term effects, recurrence and malignancy rate varies; however, the report does not include pregnant patients [10]. The diagnosis of PA during pregnancy is infrequent. In a large study querying the International Cancer in Pregnancy registration, low grade astrocytoma was found in 22% of the 27 cases reported between 1973 and 2012 [11]. PA is histologically classified as grade I by the World Health Organization (WHO). There is no available evidence demonstrating that pregnancy increases the growth of Grade I PA as it has been documented with Grade II gliomas [12].

We present a case of a cerebellar tumor discovered at 26 week's gestation in an otherwise healthy 31-year-old woman. This patient had no clinical life history of neurological events, and went through a full term previous pregnancy with no signs or symptoms of an intracranial space occupying mass. The tumor was diagnosed originally via cellular smears from fluid aspirated from the cyst as a Grade I pilocytic astrocytoma. This was reconfirmed by tissue diagnosis at the time of the surgical resection. The immediate maternal and neonatal results have been good. We consider the primary diagnosis of pilocytic astrocytoma in a pregnant adult infrequent, thereby this case submission. Traditionally, brain tumors during pregnancy are evaluated and treated by a multidisciplinary team as was in this case. These tumors are generally diagnosed in very young

individuals, 75% occurring in the first two decades of life. Di Muzio et al. reported that PAs are the most common primary brain tumors of childhood and account for approximately 70% to 80% of all cerebellar astrocytomas and for 2% of all brain tumors [13]. They may occur in any area of the brain stem or spine where astrocytes are present. A classic juvenile grade I astrocytoma is generally a benign non infiltrating tumor of slow growth and usually follows a rather protracted course.

Brain tumors in pregnancy pose a diagnostic and therapeutic dilemma to the treatment team due to the scant population based studies and evidence-based neurosurgical guidelines for pregnant patients. An extensive retrospective cohort study identified 437 benign brain tumors among 19 million pregnancy-related admissions through the nationwide inpatient sample (NIS) [14]. No report of a Grade I pilocytic astrocytoma in pregnancy is included (**Table 1**).

Table 1 Intracranial tumors in pregnancy, no pilocytic astrocytoma included

Author	Study	# of cases	Histology	Resection	Delivered
Terry AR [14]	Retrospective	437	Benign (?)	19%	61%
Cohen-Gadol A [2]	Retrospective	34	GBM, Astro II and III	78%	57%

A diagnosis of hyperemesis gravidarum showed an OR ratio of 2.8 in the presence of benign brain tumors in pregnancy. Similarly, there is an increased risk for cesarean delivery (OR 2.8) and hospitalization (OR 4.3). One third of those patients ended with a neurosurgical approach either during, at the time of delivery or in the post-partum period, depending on the maternal-fetal clinical situation. Pregnancy complications were not more likely to occur in these surgical patients. The authors of the report emphasize that additional research is needed to improve the understanding of obstetric risk in these patients

and to further assist with counselling, monitoring, treatment and follow up. Currently there are no evidence-based guidelines to follow on patients diagnosed with brain tumors during pregnancy. Due to the specificity of the diagnosis we selected to limit our search for documented outcomes of pilocytic astrocytomas (PA) WHO Grade I in pregnancy, surgical and clinical outcomes in adults. A number of existing studies have not addressed the combination of PA and pregnancy [15-17] (**Table 2**).

Table 2 Cerebellar pilocytic astrocytoma, Non pregnant patients

Author	Study	# of cases	Complete Resection	Recurrence	Algorithm
Dirven [15]	Retrospective	73	69%	19%	Offered
Cyrine [16]	Retrospective	32	43.7%	3.1%	
Ye [10]	Retrospective	20		30%	
Galgano [18]	Case	1	Drain, resection		

Extant case reports and reviews of the literature have traditionally included single case reports or all-inclusive benign intracranial tumors during pregnancy. The optimal treatment of PAs is not limited to optimal resection, if the tumor location allows it with careful handling to avoid spread of tumor cells, metastasis and possible need for radiation therapy. It also includes serial post treatment follow up with MRI to elicit any local or regional tumor changes or recurrence. PA is usually considered a benign childhood tumor. Some clinical presentations such as partial resection, brainstem location and adult age at discovery have a worse prognosis [15,16]. Overall surgical and progression-free survival rates were reported as 87% and 60% respectively. Unfavourable outcomes were observed in adults compare with a younger population [7]. Less than 5% of pilocytic astrocytomas progress towards malignancy [18]. Due to the absence of clinical indication of an intracranial space occupying mass in this patient, we selected to submit the report to alert clinicians to the need to rule out brain tumor during pregnancy. During pregnancy, the diagnosis of hyperemesis gravidarum may need reconsideration even before overt neurological signs and symptoms appear in the

advanced second trimester. It is plausible that this tumor was present in this patient since her infancy and remained silent. Conversely, there is no evidence that gestational changes may influence the behaviour of the tumor. Rarely intratumor hemorrhage occurs in pilocytic astrocytomas [19]. White et al reported pilocytic astrocytomas diagnosed in adults, mean age 23 years old, 8% with hemorrhage, 6 of them in female patients, none of them diagnosed during pregnancy [20].

Conclusion

The diagnosis of a maternal intracranial tumor during pregnancy is infrequent. A pilocytic astrocytoma diagnosed during pregnancy at age 31 presents a distinct challenge for the treatment team. These tumors are usually discovered during childhood and are considered benign. In the adult the behaviour of the tumor and the association with genetic aberrations increase the chance to become malignant or recur [21]. That is the primary reason for this case report. The histopathology of the tumor and the patient's age need a complete understanding of the molecular variations of

pilocytic astrocytomas and when needed, search for molecularly targeted treatment if available [16] (Table 3).

Table 3 Astrocytoma in pregnancy (low grade)

Author	Study	# of cases	Histology	Treatment
Verheecke [11]	retrospective	6	low grade II astrocytoma	resection, RT*, CT*
Hong [17]	case	1	pilocytic astrocytoma gr 1	resection
Haas [4]	retrospective	9	astrocytoma I	

*RT. Radiotherapy *CT chemotherapy

Genetic counselling may be desirable. We understand that there are no guidelines for the treatment of maternal brain tumors in pregnancy. Nevertheless, guidelines are usually not binding or otherwise they are not followed religiously. In the era of evidence-based medical practice we offer the following teaching points for this case; 1. In the rare case of a maternal brain tumor, a multidisciplinary team must be assembled to arrive at a prompt diagnosis, adequately counsel the family, and decide a course of therapy. 2. If feasible, and according with the established diagnosis, continue the care of the pregnancy while be prepared for any maternal or fetal medical or surgical emergent contingency. The diagnosis allows for targeted therapy or conservative treatment as appropriate. 3. A pregnant woman with persistent and unremitting nausea, vomiting, dizziness must be fully evaluated in spite of the rarity of a brain tumor in pregnancy. These concerns are usually followed by the treatment team and may serve as a springboard to establish standards of care. There is an opportunity for further research regarding the variable behaviors of these juvenile tumors during pregnancy. Short and long term follow up, expanded patient work up to arrive at a complete picture with clinical relevance for additional treatment when indicated and long term prognosis follows. The authors recommend that each new case of PA in pregnancy and its clinical outcome be reported to the National Registry to allow pertinent clinical information to be readily available for obstetrical practitioners and the entire health care team.

References

- Lew PS, Tan WC, Tan WK, Tan HK (2010) Dilemmas in management of brain tumors in pregnancy. *Annals Academy of Medicine* 39: 64-65.
- Cohen-Gadol AA, Friedman JA, Friedman JD, Tubbs RS, Munis JR, et al. (2009) Neurosurgical management on intracranial lesions in the pregnant patient: a 36-year institutional experience and review of the literature. *J Neurosurg* 111: 1150-1157.
- Ravindra VM, Braca JA, Jensen RL, Duckworth EAM (2015) Management of intracranial pathology during pregnancy: case example and review of management strategy. *Surg Neurol Int* 6: 43-56.
- Haas JF, Janisch W, Staneczek W (1986) Newly diagnosed primary intracranial neoplasms in pregnant women: a population based assessment. *J Neurol Neurosurg and Psychiatry* 49: 874-80.
- Webb JAW, Thomsen HS (2013) Gadolinium contrast media during pregnancy and lactation. *Acta Radio* 54: 599-600.
- Giovanini MA, Mickle JP (1996) Long term access to cystic brain stem lesions using the Ommaya reservoir: technical case report *Neurosurgery* 39: 404-407.
- Cushing H (1931) Experiences with the cerebellar astrocytomas, a critical review of 76 cases. *Surg. Gynecol-Obstet* 52: 129-204.
- Available from <http://www.hersentumor.nl> access August 10, 2016.
- Bar EE, Lin A, Tihan T, Burger PC, Eberhardt CG (2008) Frequent gains at chromosome 7q34 involving BRAF in pilocytic astrocytoma. *J Neuropathol Exp Neurol* 67: 878-887.
- Ye JM, Ye MJ, Kranz S, Lo P (2014) A 10-year retrospective study of surgical outcomes of adult intracranial pilocytic astrocytoma. *J. Clin Neurosci* 21: 2160-2164.
- Verheecke M, Halaska MJ, Lok CA, Ottevanger PB, Fruscio R, et al. (2014) Primary brain tumors, meningiomas and brain metastasis in pregnancy: report of 27 cases and review of literature. *Eur J Canc* 50: 1462-1471.
- Pallud J, Mandonnet E, Deroulers C, Fontaine D, Badoual M, et al. (2010) Pregnancy increases the growth rates of World Health Organization grade II gliomas. *Ann Neurol* 67: 398-404.
- Di Muzio B, Gaillard F (2015) MRI grading versus histology: predicting survival of World Health Organization grade II-IV astrocytomas. *AJNR AM J Neuroradiol* 36: 77-83.
- Terry AR, Barker II FG, Leffert L, Bateman BT, Souter I, et al. (2012) Outcomes of hospitalization in pregnant women with CNS neoplasms: a population-based study. *Neuro Oncol* 14: 768-776.
- Dirven CM, Mooij JJ, Molenaar WM (1997) Cerebellar pilocytic astrocytoma: a treatment protocol based upon analysis of 73 cases and a review of the literature *Childs Nerv Syst* 13: 17-23.
- Cyrine S, Sonia Z, Mounir T, Batterededine S, Kalthoum T, et al. (2013) Pilocytic astrocytoma: a retrospective review of 32 cases. *Clin Neurol Neurosurg* 115: 1220-1225.
- Hong CS, Lehman NL, Sauvagean E (2014) A pilocytic astrocytoma mimicking a clinoidal meningioma. *Case reports in Radiology* Article ID 524574.
- Dirks PB, Jay L, Becker LE (1994) Development of anaplastic changes in low grade astrocytomas of childhood. *Neurosurgery* 34: 68-78.
- Galgano M, Padalino DJ, Fullmer J, Krishnamurthy S (2014) Acute neurological deterioration in an adult with a cerebral pilocytic astrocytoma accompanied by intratumoral hemorrhage,

- subdural hematoma and obstructive hydrocephalus *Cruces* 6: e235.
20. White JB, Piegras DJ, Scvheithauer BW, Parisi JE (2008) Rate of spontaneous hemorrhage in histologically proven cases of pilocytic astrocytoma. *J Neurosurg* 108: 223-226.
21. Sadighi Z, Slopis J (2013) Pilocytic astrocytoma: a disease with evolving molecular heterogeneity. *J Child Neurol* 28: 625-632.